

Pearls for Hair loss

Natasha A. Mesinkovska MD PHD

Vice Chair, Clinical Research
Department of Dermatology
University of California, Irvine
2023 West Coast Derm

Disclosure

- **No conflict of interest**

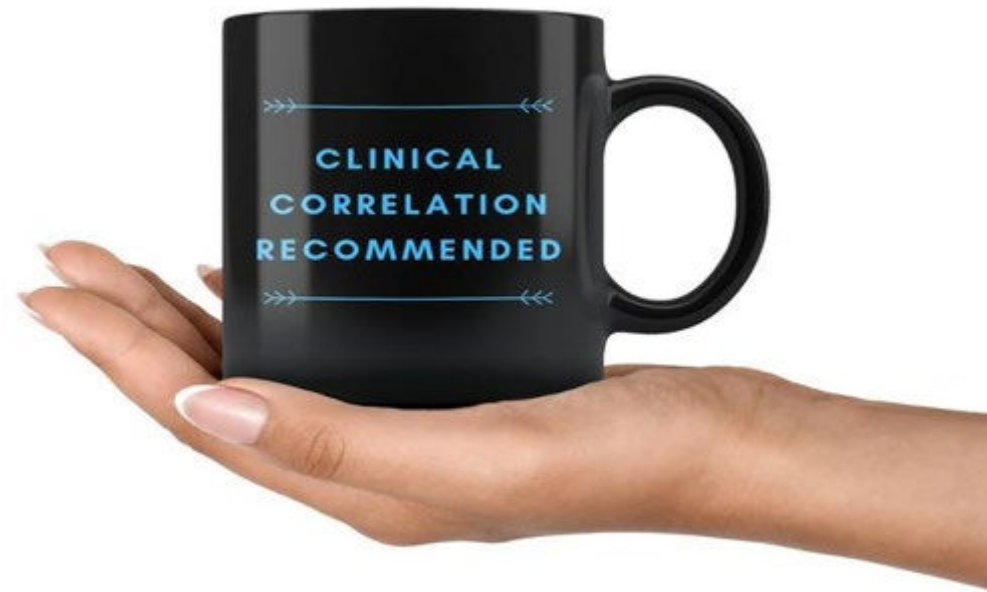- **National Alopecia Areata Foundation**

- **Chief Scientific Officer 2015-2022**



- **University of California Irvine**

- **Principal Investigator: Abbvie, Arcutis, Arena, BMS, Concert, Galderma, Merz, Lilly, Kadmon, Novartis, Pfizer.**
 - **Advisory Board,/Honoraria/Fees: Arena, Galderma, Lilly, Nutrafol, Concert, Loreal, Pfizer**



>>—————<<
CLINICAL
CORRELATION
RECOMMENDED
—————>><<

The long awaited alopecia biopsy report

FINAL DIAGNOSIS:

A. Skin, right frontal scalp, punch biopsy: **Non-scarring alopecia (see comment)**

- **There is differential...**
- **These are features of nonscarring alopecia, and the differential diagnosis includes telogen effluvium, androgenetic alopecia, or chronic (burnt out) state of alopecia areata.**
- **Clinical correlation is recommended”**

When things don't improve

Diagnosis

Is it "only" AGA or not?

Agenda: PEARLS

1. ASK
2. EXAM
3. WORK UP



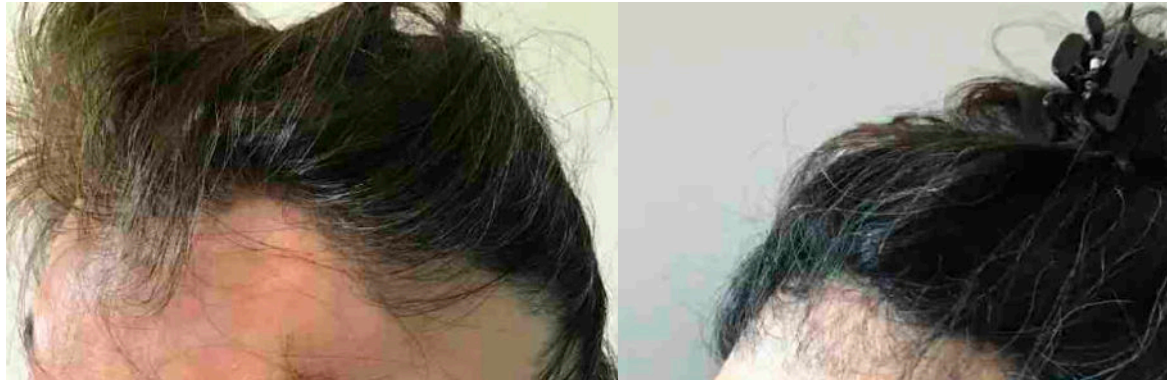Tip 1: Ask about allergies



Tip 1: Ask about allergies

Acute Flare of AD and hair loss

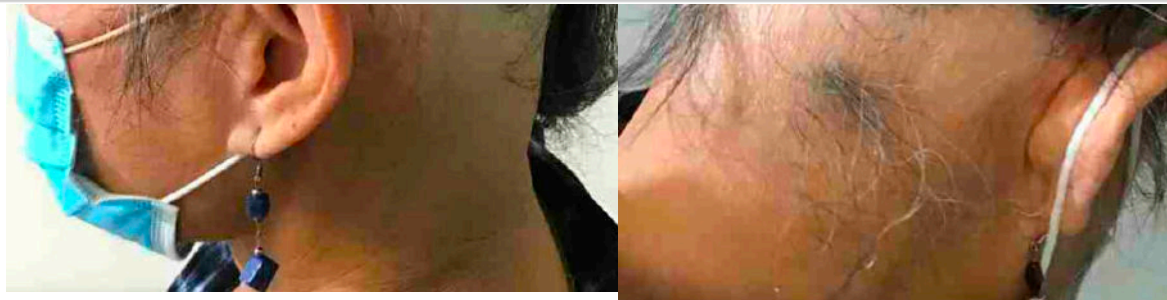
Hx
AD
AA
Allergies



Immunoglobulin E

<OR=114 kU/L

4,255 ▲



Allergen Profile With Total IgE, Respiratory–Area 13

IgE allergy testing for:

- **Alder (t2)**
- ***Alternaria alternata* (a mold) (m6)**
- ***Aspergillus fumigatus* (m3)**
- **Bermuda grass (g2)**
- **Cat dander (e1)**
- ***Cladosporium herbarum* (m2)**
- **Cocroach (i6)**
- **Common ragweed (short) (w1)**
- **Cottonwood (t14)**
- ***Dermatophagoides farinae* (d2)**
- ***Dermatophagoides pteronyssinus* (d1)**
- **Dog dander (e2)**
- **Elm (t8)**
- **Johnson grass (g10)**
- **Mountain cedar (t6)**
- **Mouse Urine Proteins (e72)**
- **Mugwort (sagebrush) (w6)**
- **Mulberry (t70)**
- **Oak (t7)**
- **Olive (t9)**
- ***Penicillium notatum* (m1)**
- **Rough pigweed (w14)**
- **Russian Thistle (prickly saltwort) (w11)**
- **Timothy grass (g6)**
- **Walnut tree (t10)**

Olive trees allergy

Oli	ku/L	10.90 ▲
Class Olive Tree (T9) Ige		3



Atopy is #1 Comorbidity in AA

NAAF registry

Adults

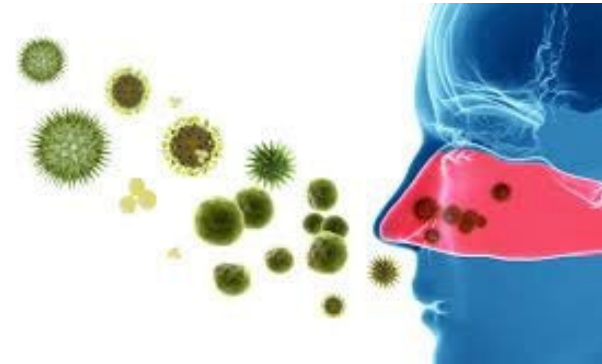
Children

Cohort	Prevalence, % Cohort	Cohort	Prevalence, %
		Current study	
Atopy [†]	38.20	Atopic dermatitis*	28.6–34.4
Thyroid disease	14.60	Vitiligo	3.14
Diabetes mellitus	11.10	Psoriasis	1.89
Psoriasis, psoriatic arthritis	6.30	Hypothyroidism	0.94
Systemic lupus erythematosus	4.30	Hashimoto's	0.63
Rheumatoid arthritis	3.90	Juvenile idiopathic arthritis	0.63
Vitiligo	2.80	Rheumatoid arthritis	0.31
Inflammatory bowel disease	2.80	Raynaud syndrome	0.31
		Celiac disease	0.31
		Ulcerative colitis	0.31

Sorrell J et al *Pediatr Dermatol.* 2017

Alopecia areata and Allergies

- **AA type 1** vs. **atopic dermatitis type 2**
- **ATOPY**
 - **AD**
 - **rhinitis**
 - **asthma**
- **AA IgE elevation**

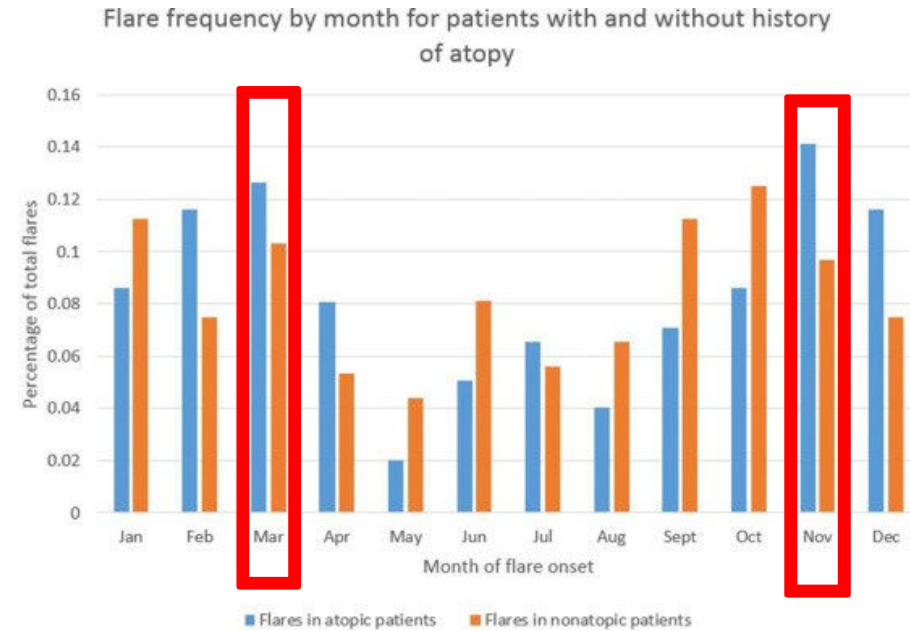


Li SF et al. Allergy to dust mites may contribute to early onset and severity of alopecia areata. Clin Exp Dermatol. 2015 Mar;40(2):171-6.
JAMA Dermatol. 2014 Sep;150(9):952-6. Diagnostic usefulness of a peribulbar eosinophilic infiltrate in alopecia areata.
Natasha A. Mesinkovska MD PhD

Seasonal “flares” in AA and atopic dermatitis



Atopic Dermatitis and AA

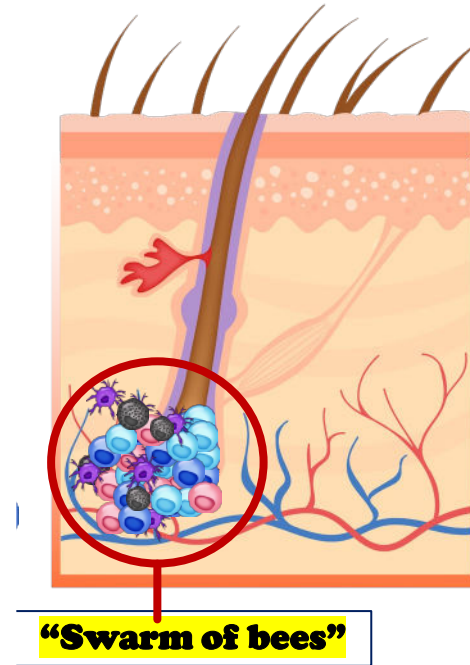


Seasonal variation and monthly patterns in Korean children with AD
[Kim M, et al. Allergy Asthma Proc. 2017 Jul 1;38\(4\):294-299.](#)

AA: WHAT are the BEES ?

Lymphocytes at hair bulb:

- **60–80% CD4+ T cells¹**
- **20–40% CD8+ T cells¹**
- **NK cells^{1,5}**
- **Dendritic cells^{2,4}**
- **Mast cell**

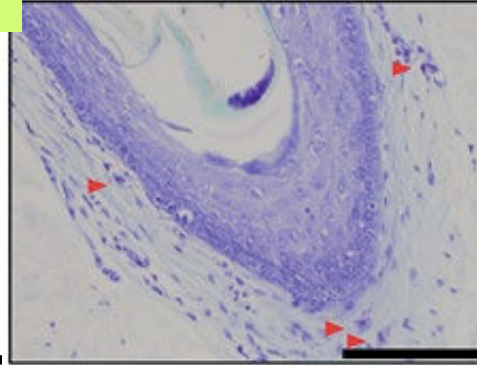


Adapted from Olayinka JT and Richmond JM. 2021.³

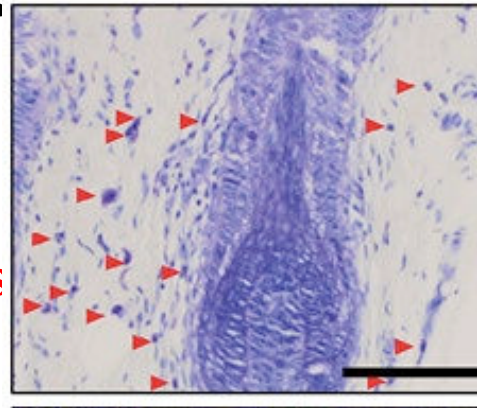
AA, alopecia areata; CD, cluster of differentiation; HF, hair follicle; NK, natural killer; Te, cytotoxic T1 T_H, T helper.
1. Ito T. *Chin Der Immunol*. 2013;34(246). 2. Shimakou T, et al. *J Autoimmun*. 2019;98:74–85. 3. Olayinka JT and Richmond JM. *Curr Rev Immunol*. 2021;27–31. 4. Bertoloni M, et al. *Exp Dermatol*. 2020;29(4):703–25.
5. Jabbari A, et al. *EBioMedicine*. 2016;7:260–7. 6. Xing L, et al. *Nat Med*. 2014;20(9):11043–9. 7. Pratt CH, et al. *Nat Rev Dis Primers*. 2017;3:17011.

Alopecia Areata Histology

- **Eosinophils**
 - Around hair bulbs
 - Acute AA **30.8%** vs. c
- **Mast cells**
 - Around hair bulbs



normal



Alopecia
Areata

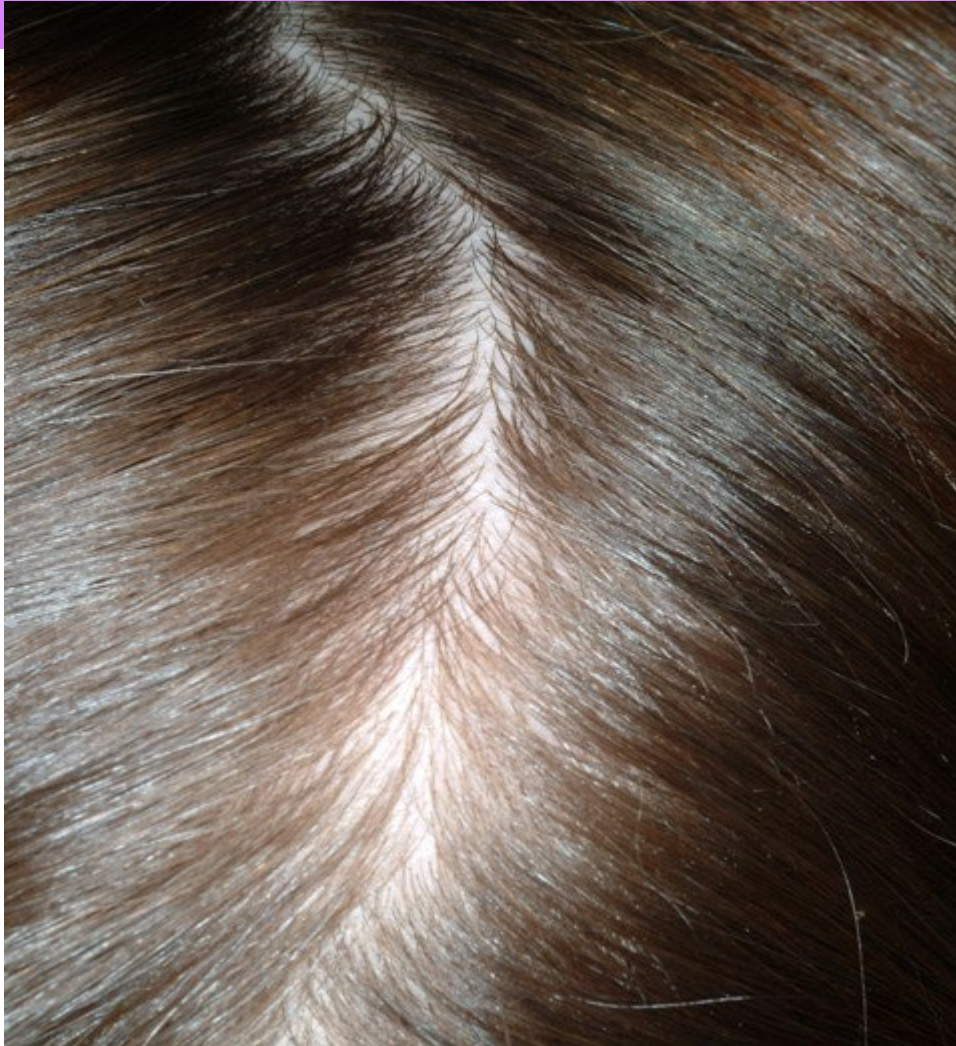Agenda: PEARLS

1. ASK

2. EXAM



1. Check The Occiput

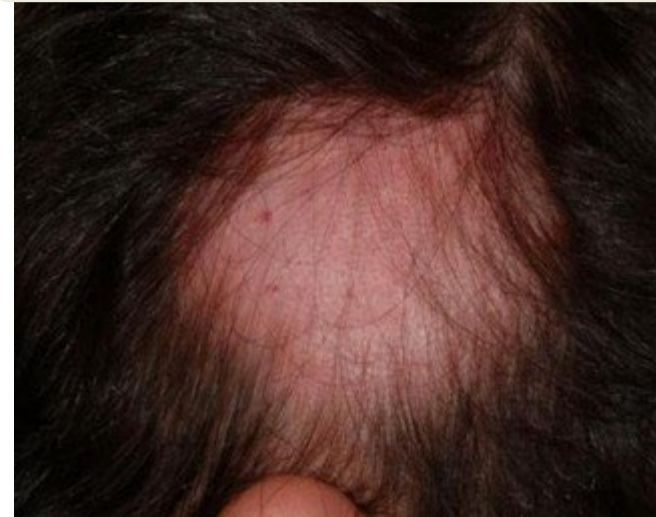

- **If that part is WIDE**
- **NOT “just AGA”**

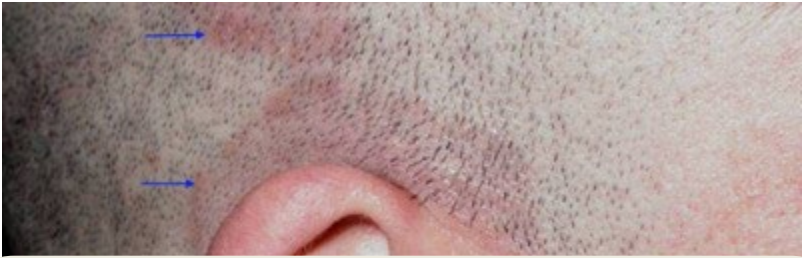Tip 2: Search for red areas

- **SUBTLE**
- **Erythematous patches and plaques**
- **Inflammation**
 - **Alopecia areata**
 - **Lupus erythematosus**
 - **Lichen planopilaris**
 - **Psoriasis**

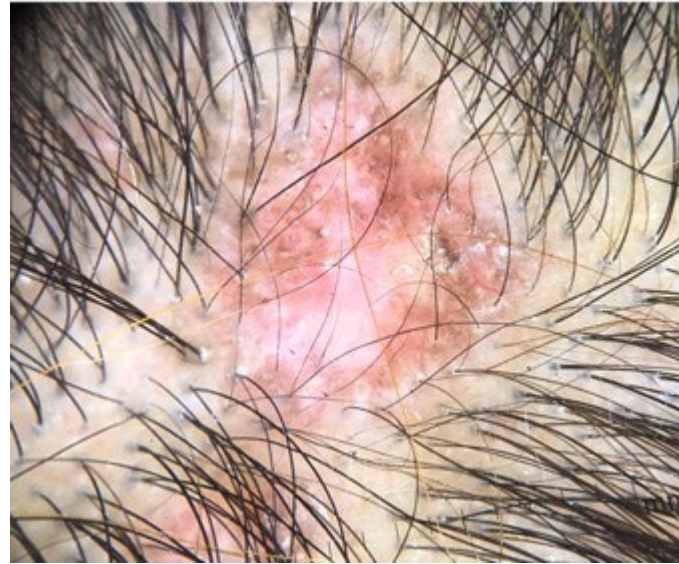
Alopecia areata



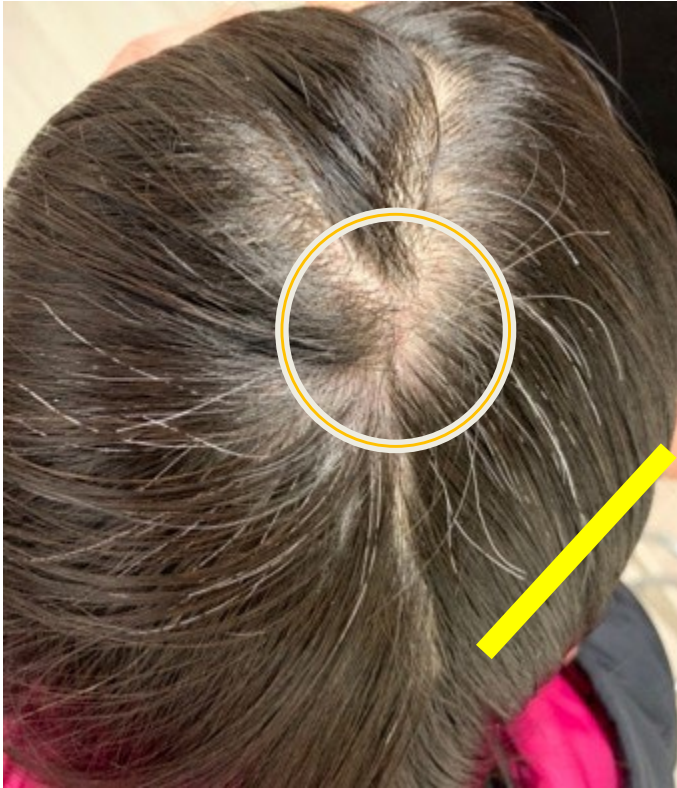Psoriasis



Discoid Lupus erythematosus



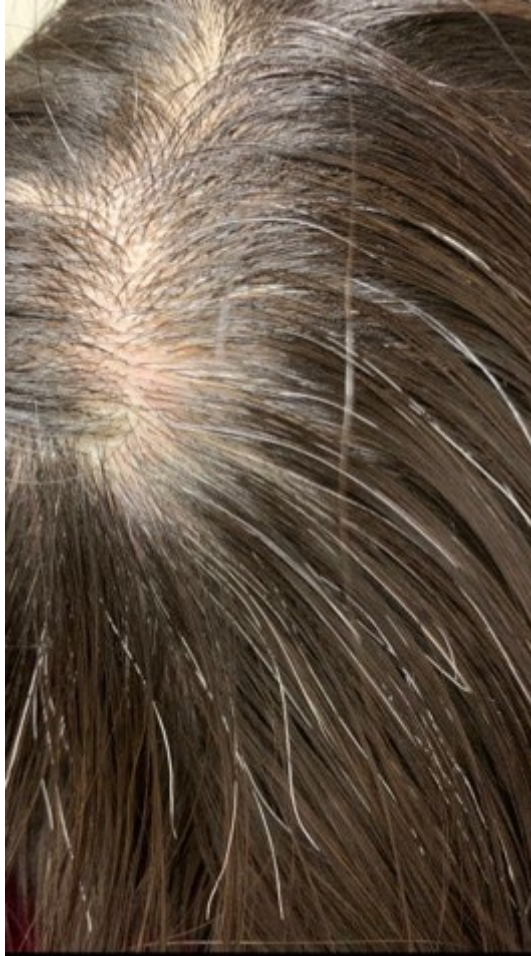Tip 3. Do not ignore grey hair tufts



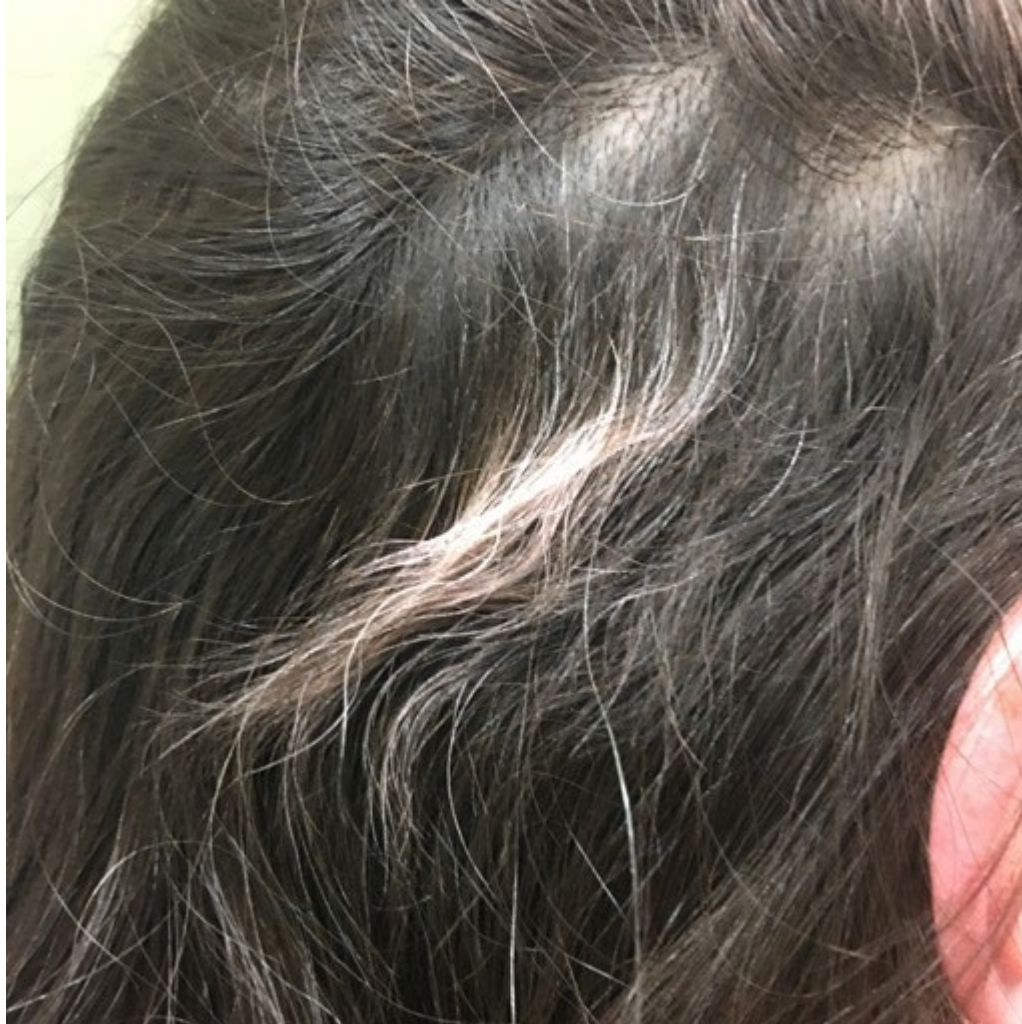- **46 yo F**
- **Nonscarring alopecia AGA vs. Telogen**
- **Erythematous patch**
- **Grey hair**

- **Alopecia areata**
- **ILK 2.5**

Tip 3. Do not ignore gray hair tuft



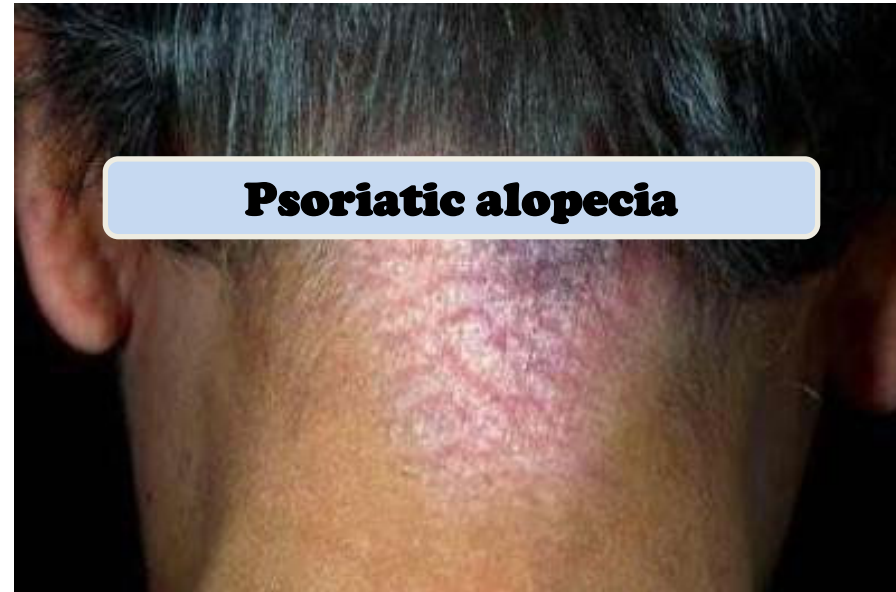
AA



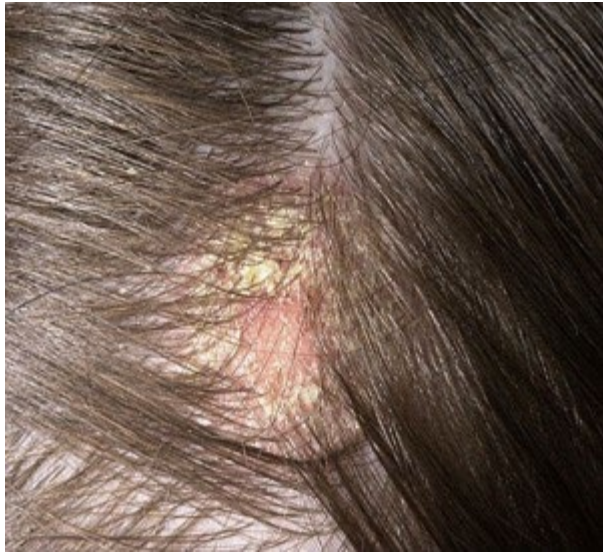• **JAKI**

Tip 4. Do not miss the scale

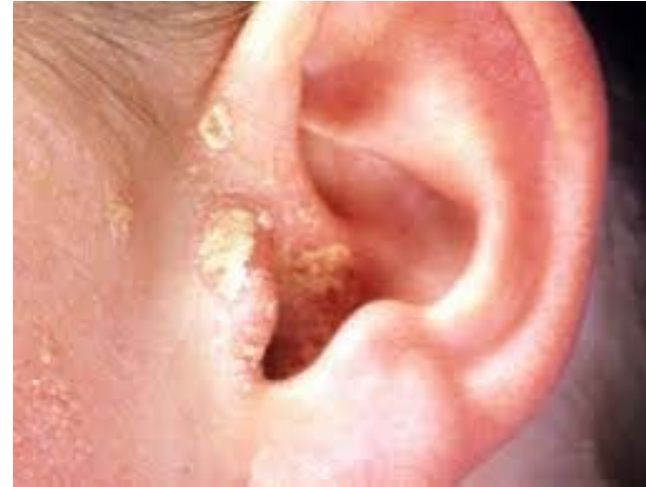- **Sebopsoriasis 28%**
- **Psoriatic alopecia**
 - **Diffuse**
 - **Patchy**
 - **Histology:**
 - **sebaceous gland atrophy?**
 - **Increased risk for alopecia areata 2.5OR**



Psoriatic plaque

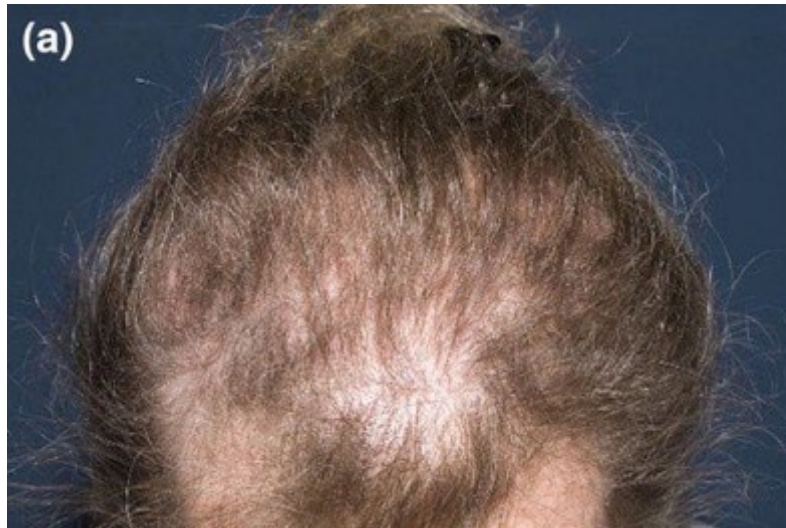


Psoriasis

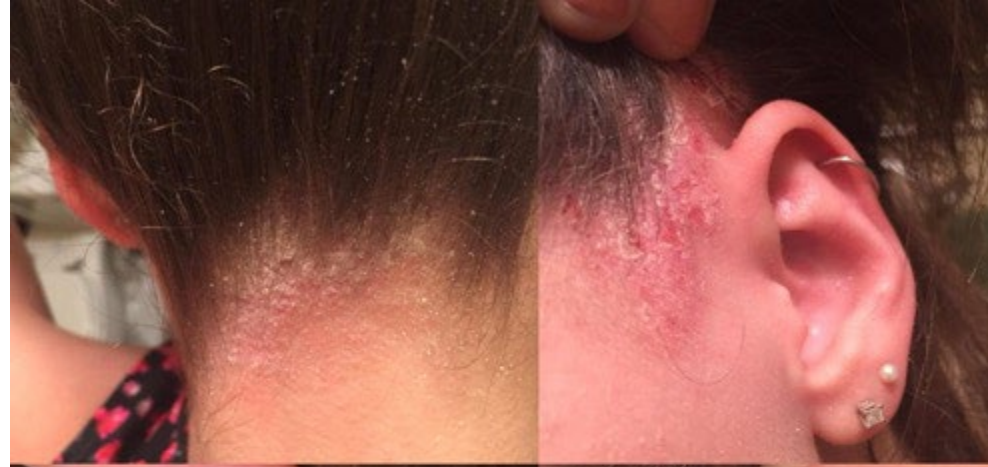

AGA ? Or Psoriatic alopecia

**Psoriatic alopecia
Regrowth with
betamethasone dipropionate/calcipotriol hydrate**



Apremilast

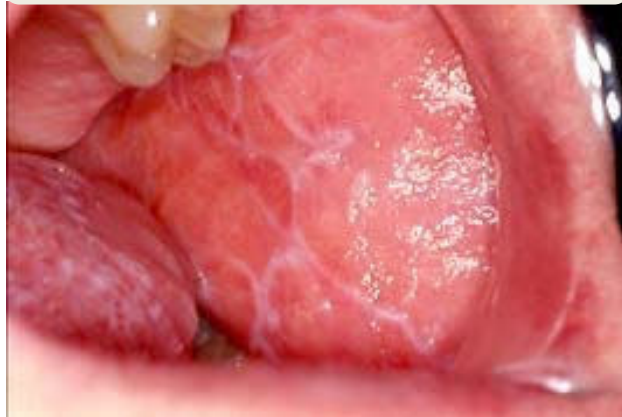

PSORIATIC ALOPECIA

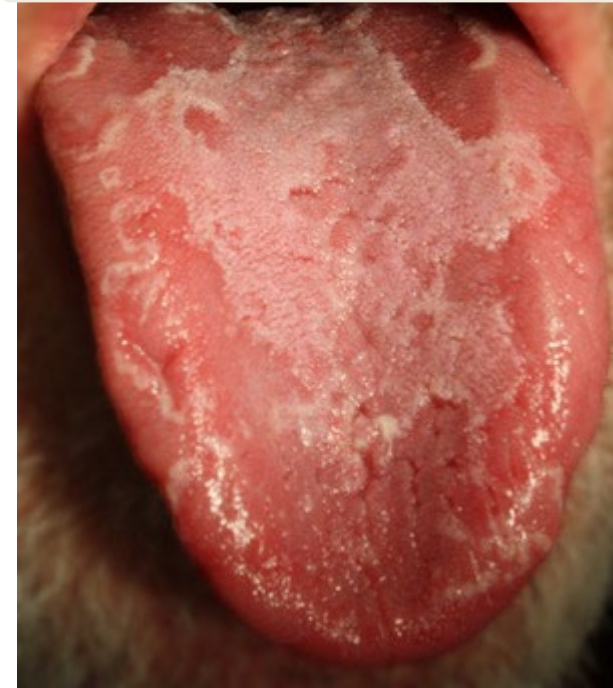Tip 5. Look around ...

- **EARS**
- **MOUTH**
- **FACE**

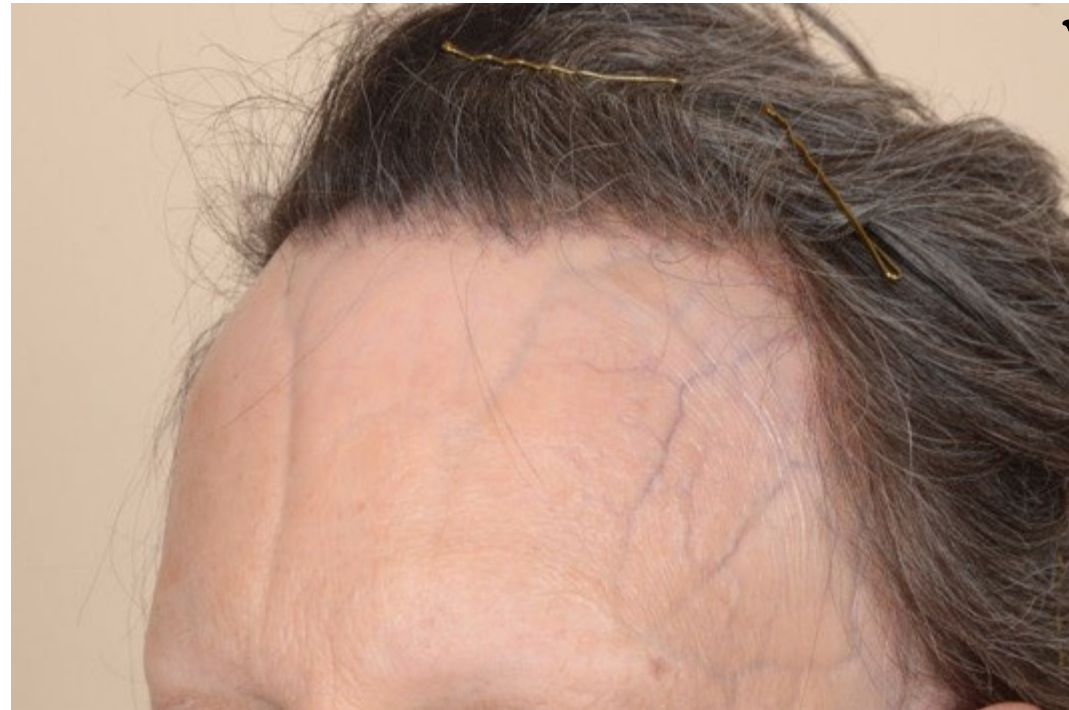Oral Lichen Planus



Geographic tongue



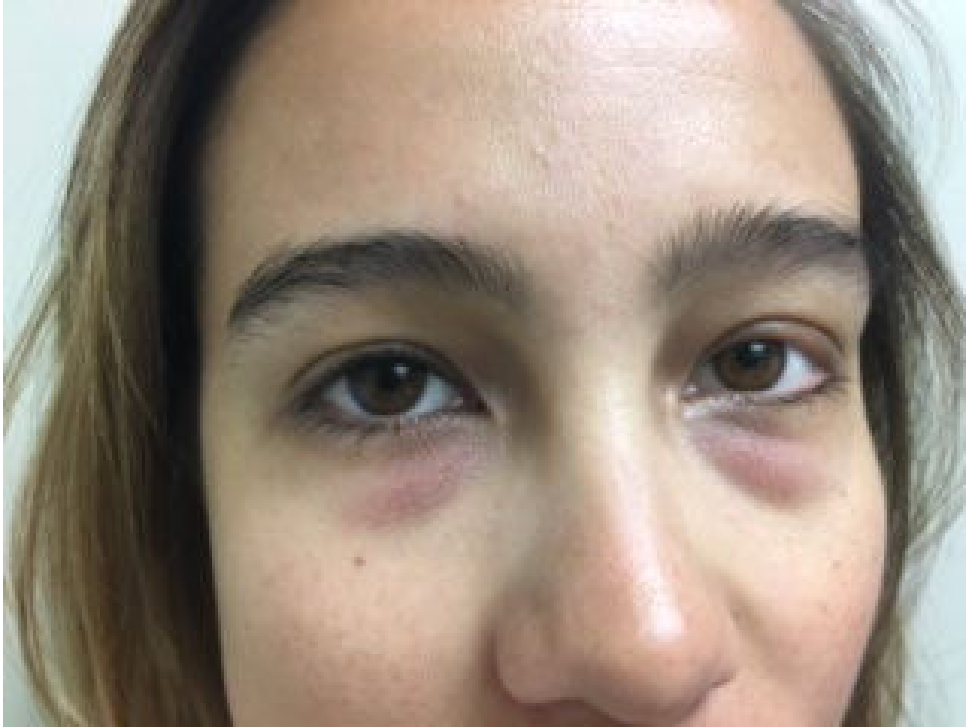Forehead lack of wrinkles



Veins

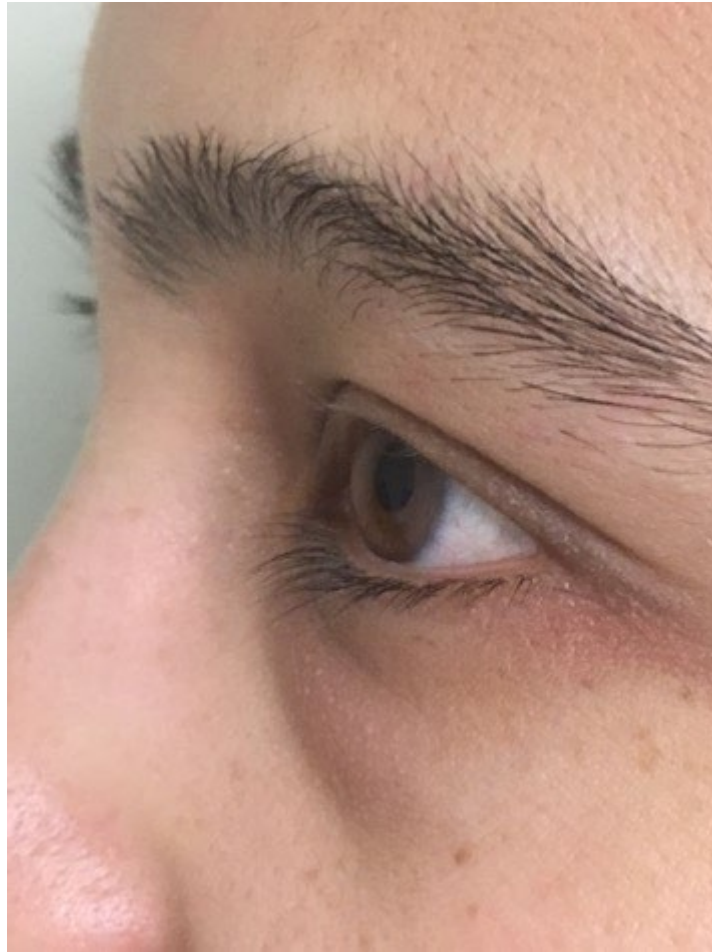FFA 62 yo

Allergic shiners?



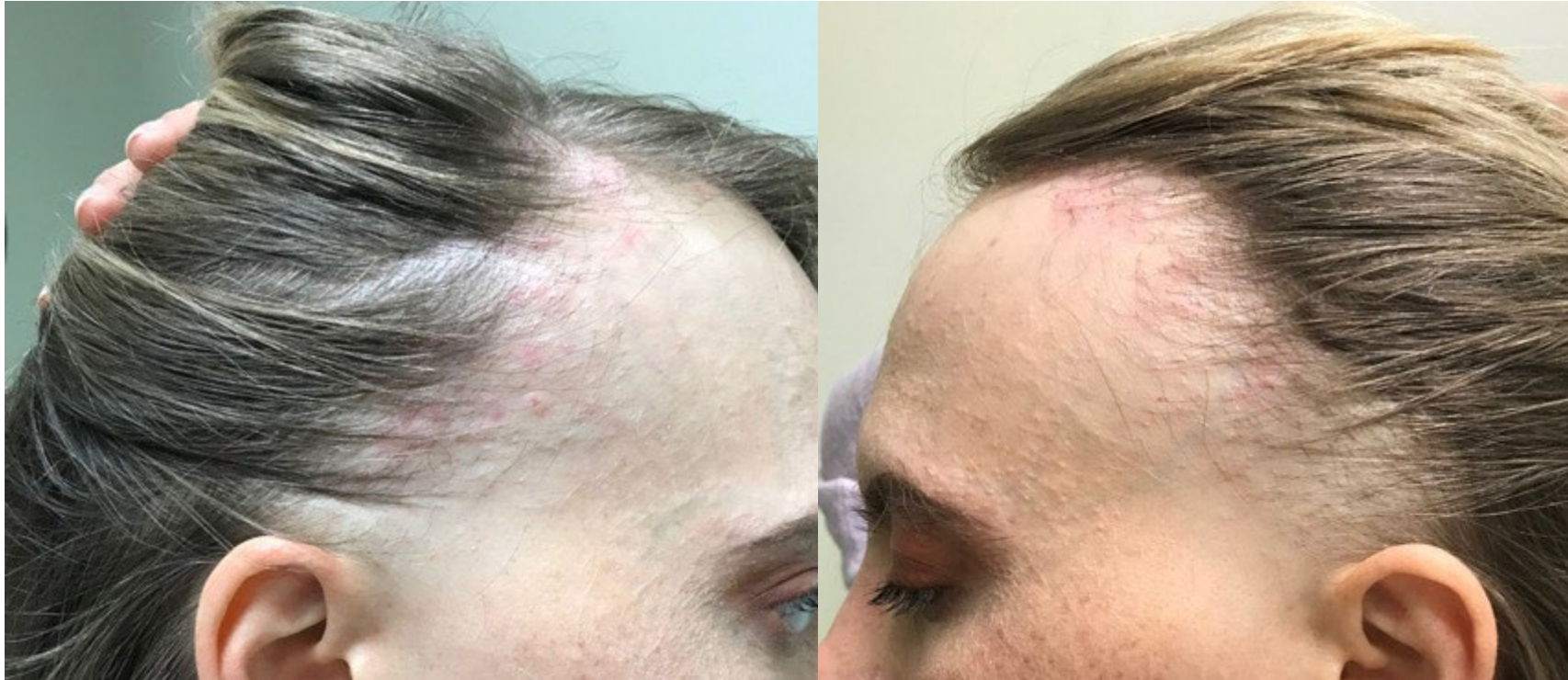Pt with AA

AA



EYELASHES??

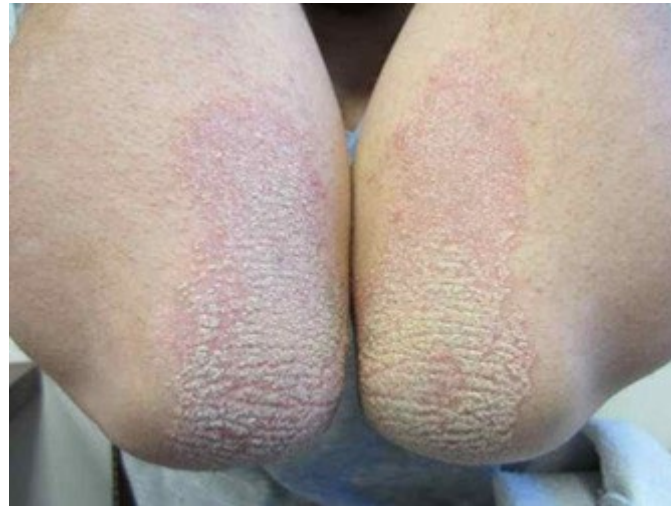FACIAL PAPULES = FFA



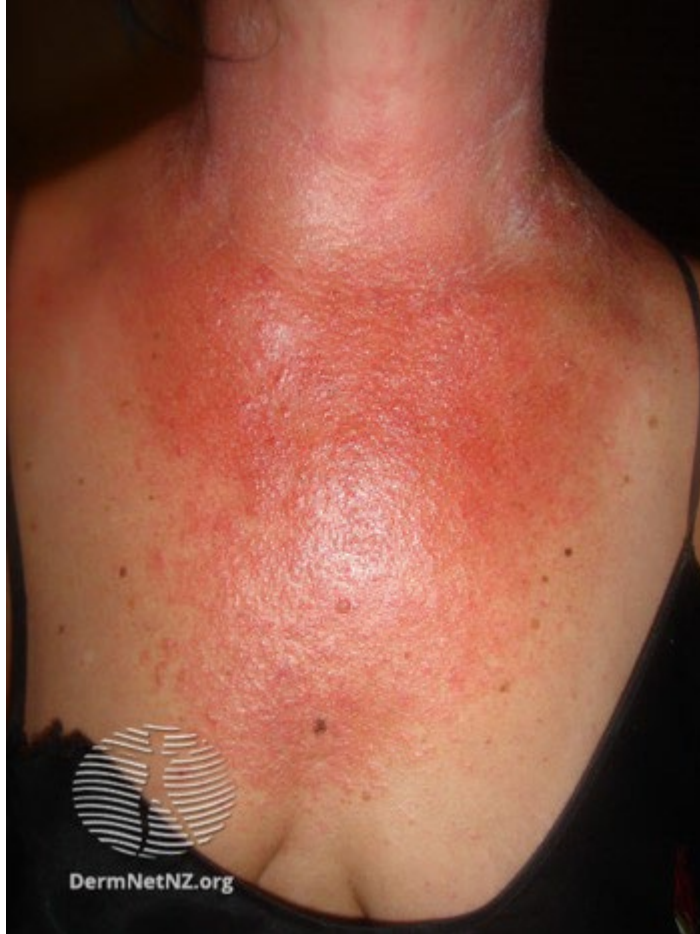28 y/o FFA patient

- **FULL BODY ?**

Psoriasis

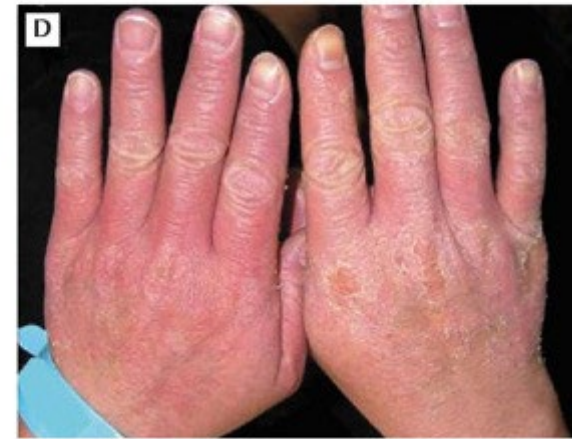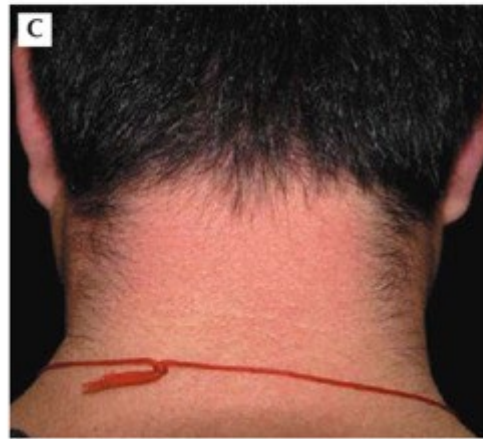
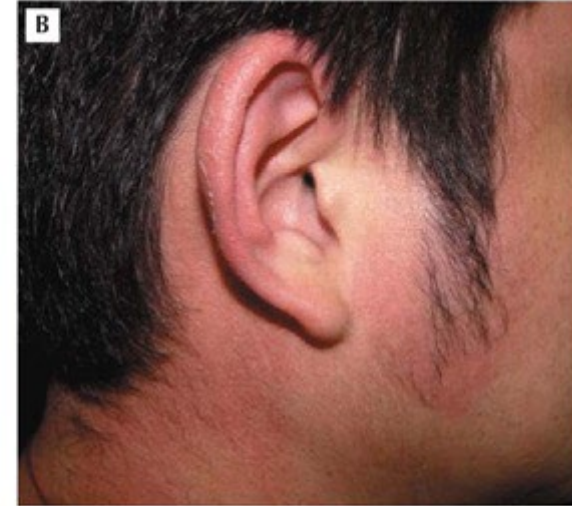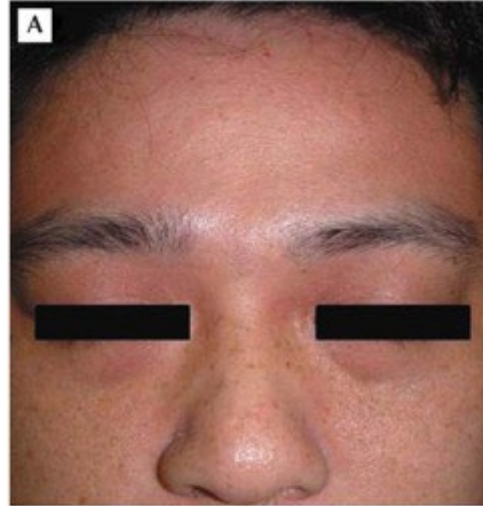


Allergy to Hair dye PPD



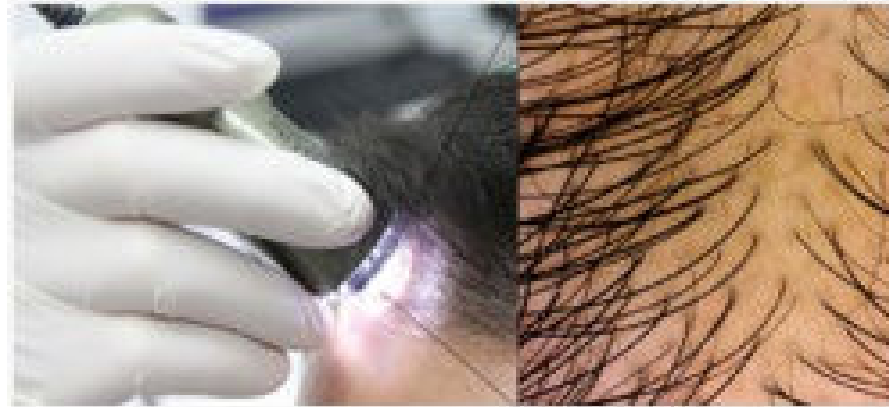ACD

- **zinc
pyrithione
in shampoo**



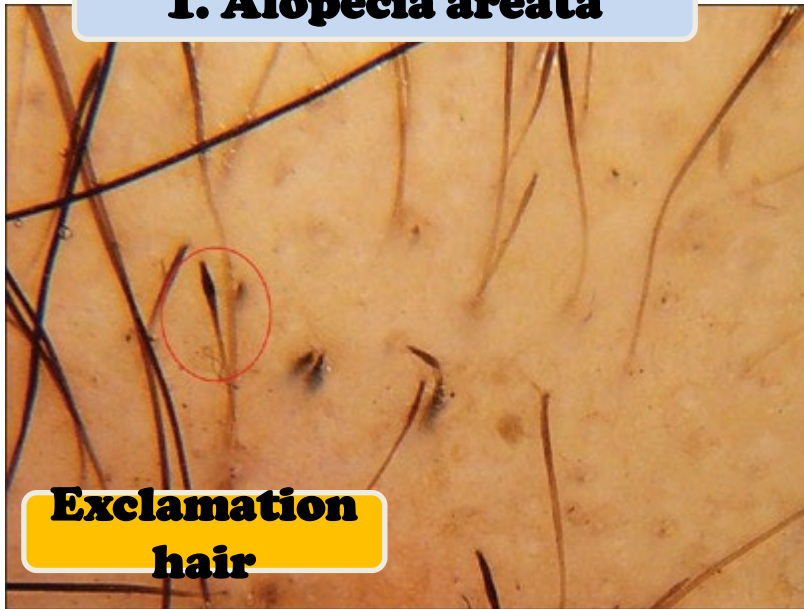
[Chih-Wei Hsieh](#), [Mei-Eng Tu](#), [Yu-hung Wu](#) Published 2010 Medicine

Tip 8: Pull out your dermatoscope

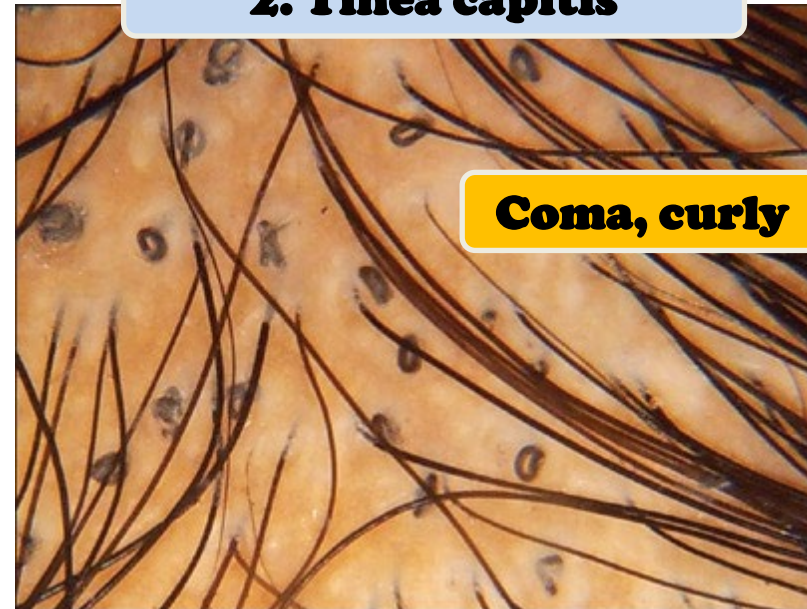


Tip 8: Pull out your dermatoscope

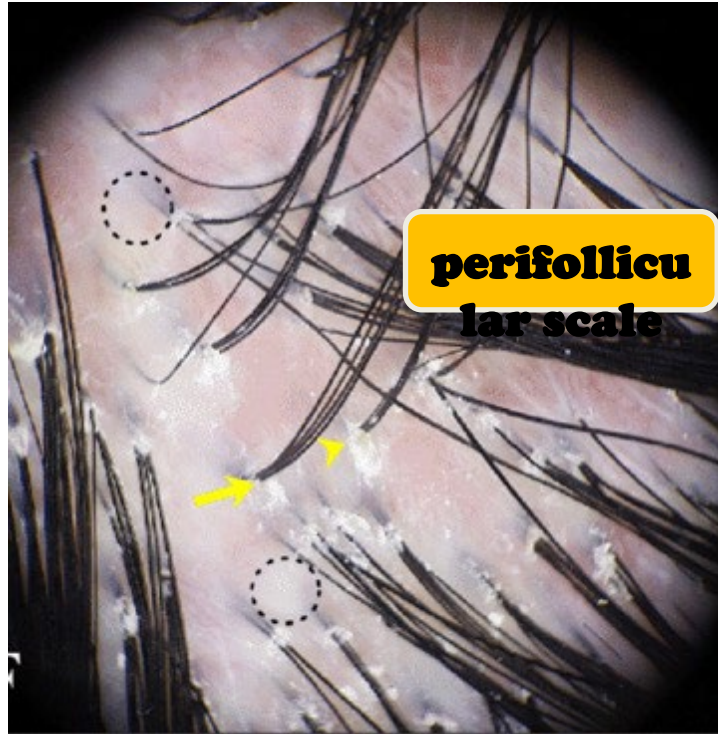
1. Alopecia areata



2. Tinea capitis



Lichen plano pilaris



Agenda: TIPS

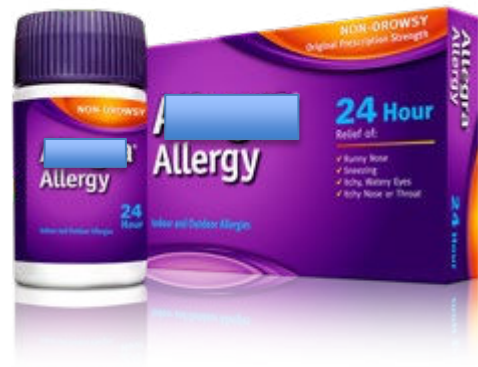1. **ASK**
2. **EXAM**
3. **WORK UP**



Check LAB: IgE

**Serum IgE biomarker in
anyone with Atopy and
Hair loss!**

Antihistamines in AA



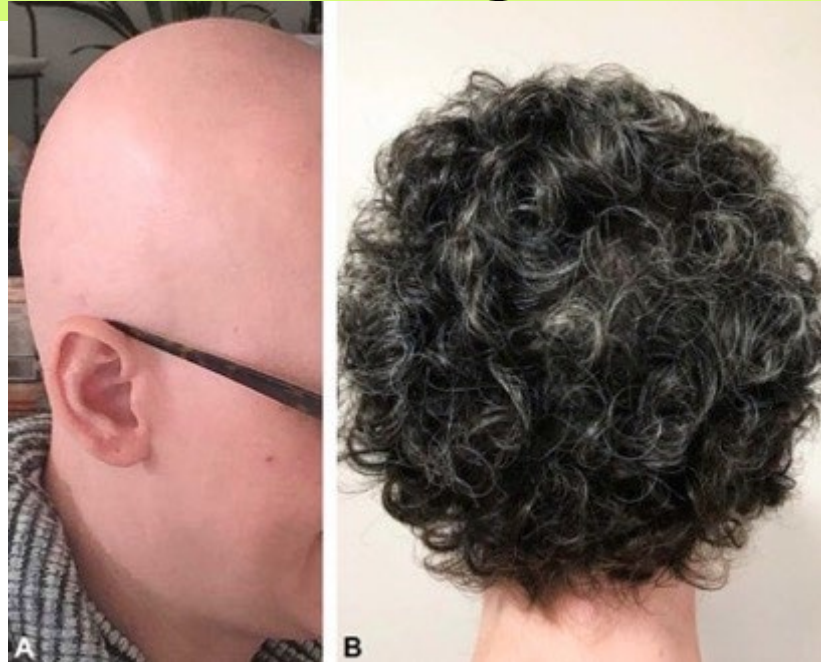**YOU HAVE ATOPY,
YOU GET AN OFFER**

- Prophylactic
- high-risk flare months

Pham C. 2019
manuscript

Dupilumab improves AA

- **Woman**
- **8 years AU**
- **30+ publications**



[Remission of alopecia universalis in a patient with atopic dermatitis treated with dupilumab](#)
Jan Smogorzewski, JAAD Case Rep. 2019 Jan 12;5(2):116-117

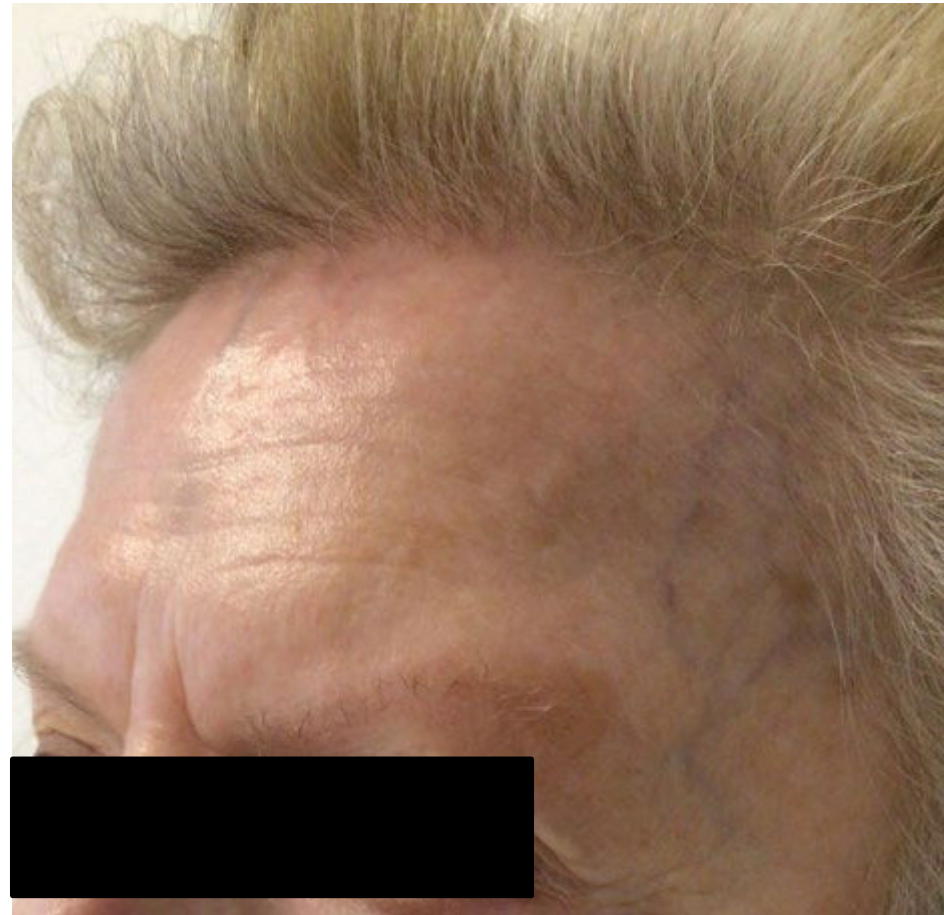Natasha A. Mesinkovska MD PhD

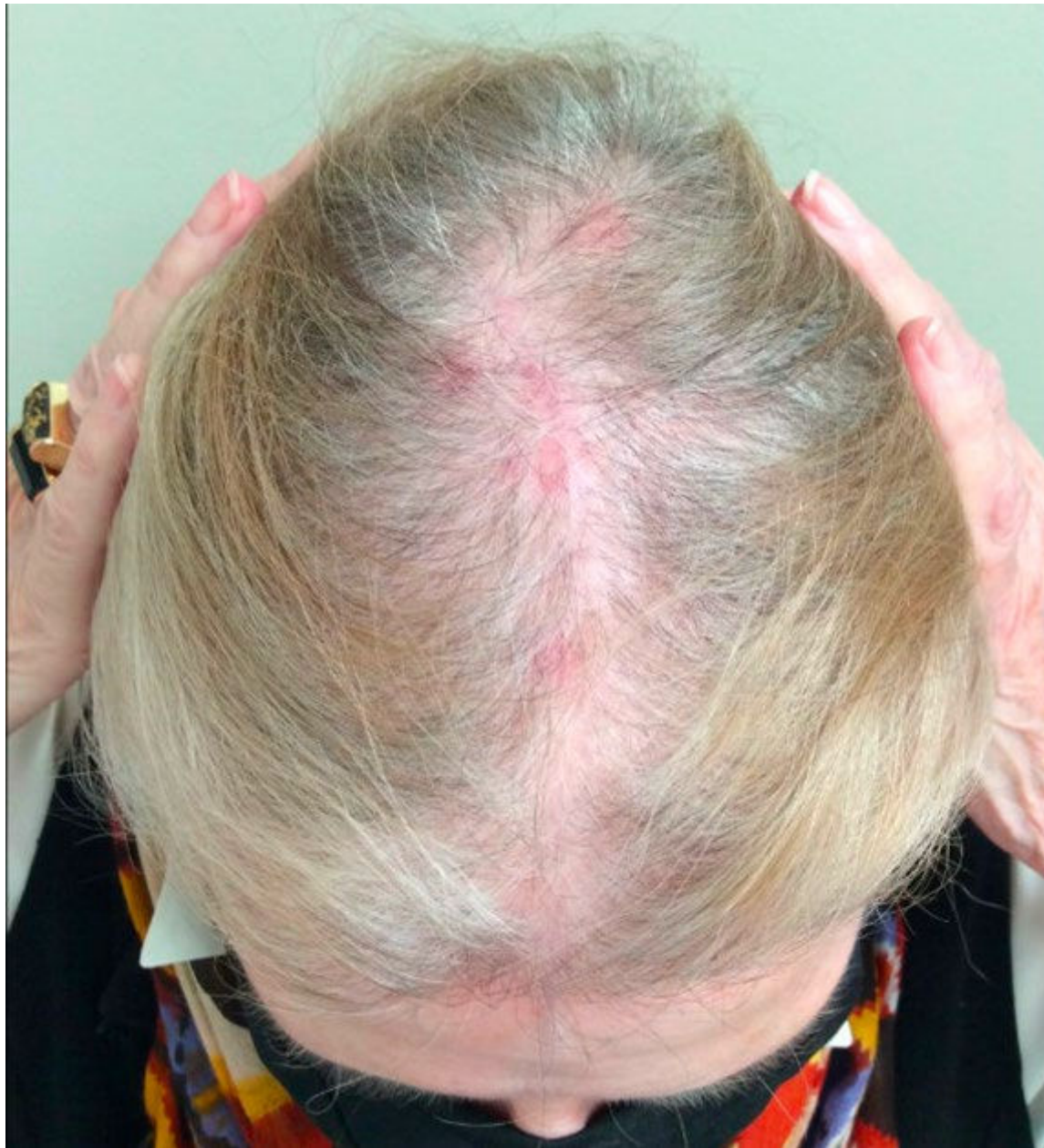Atopy, Inflammation and alopecia

- **Allergy testing!**

Tip 2: Re-biopsy

- **75yo**
- **Hx:AGA**

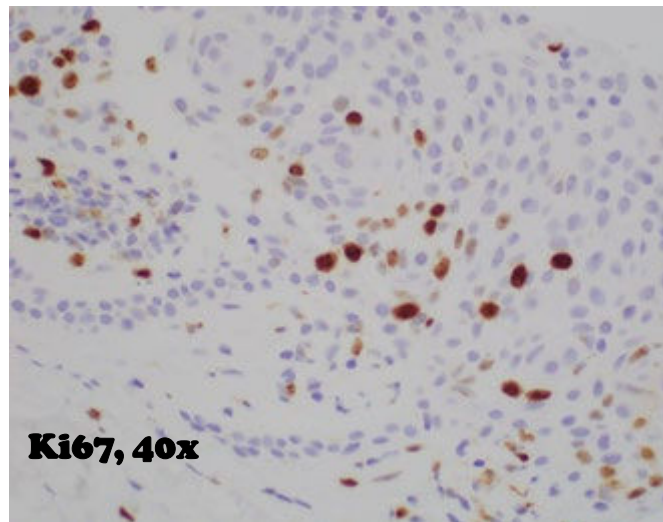
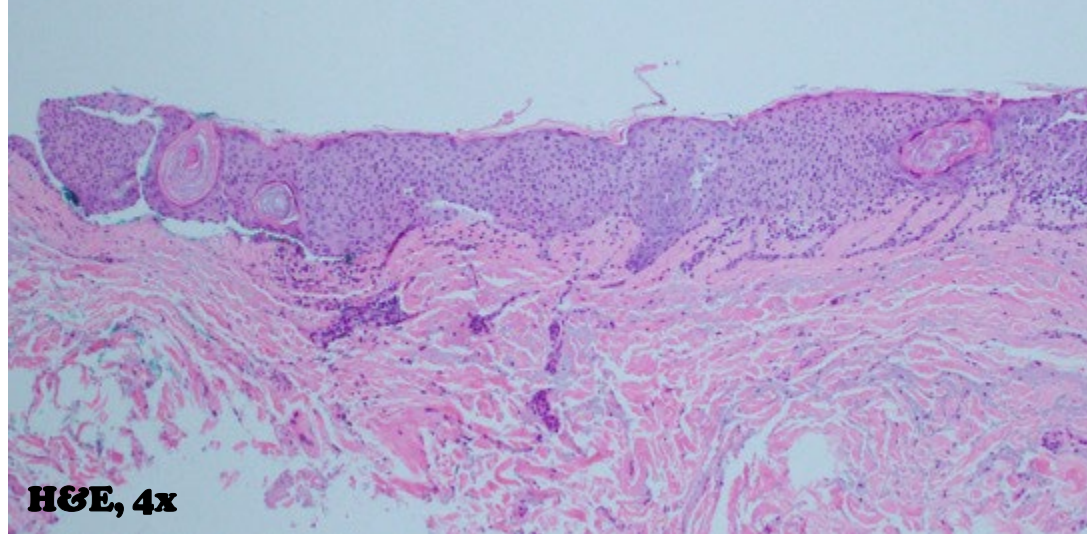




75yo F, initial presentation

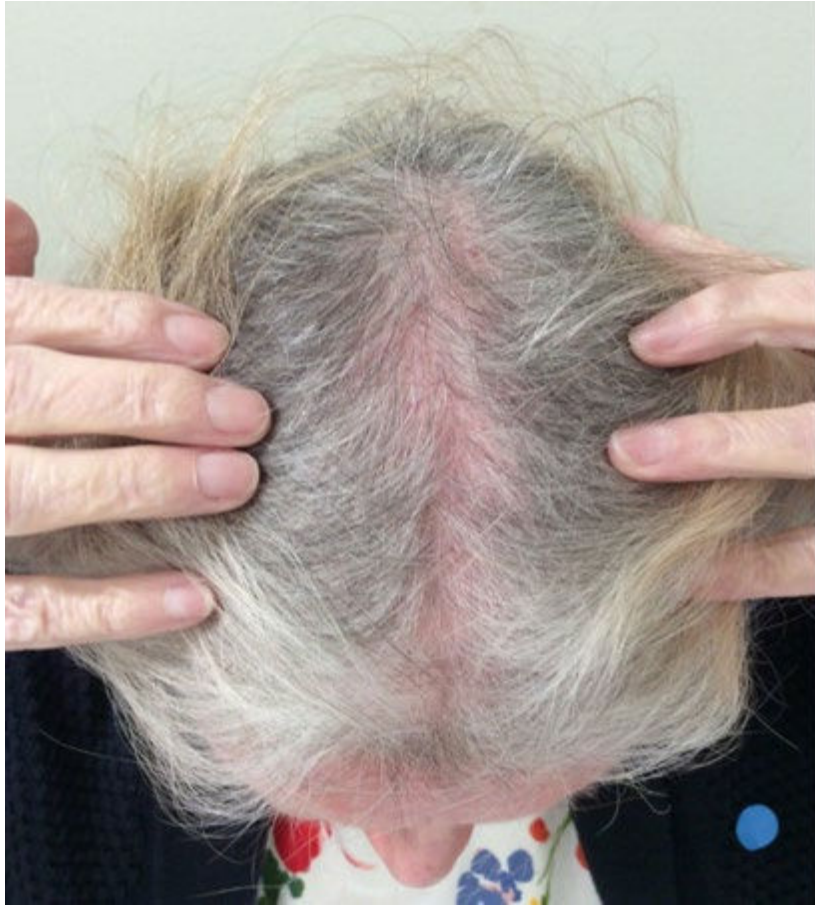Tip 2: Re-biopsy

75yo F
punch biopsy - scalp

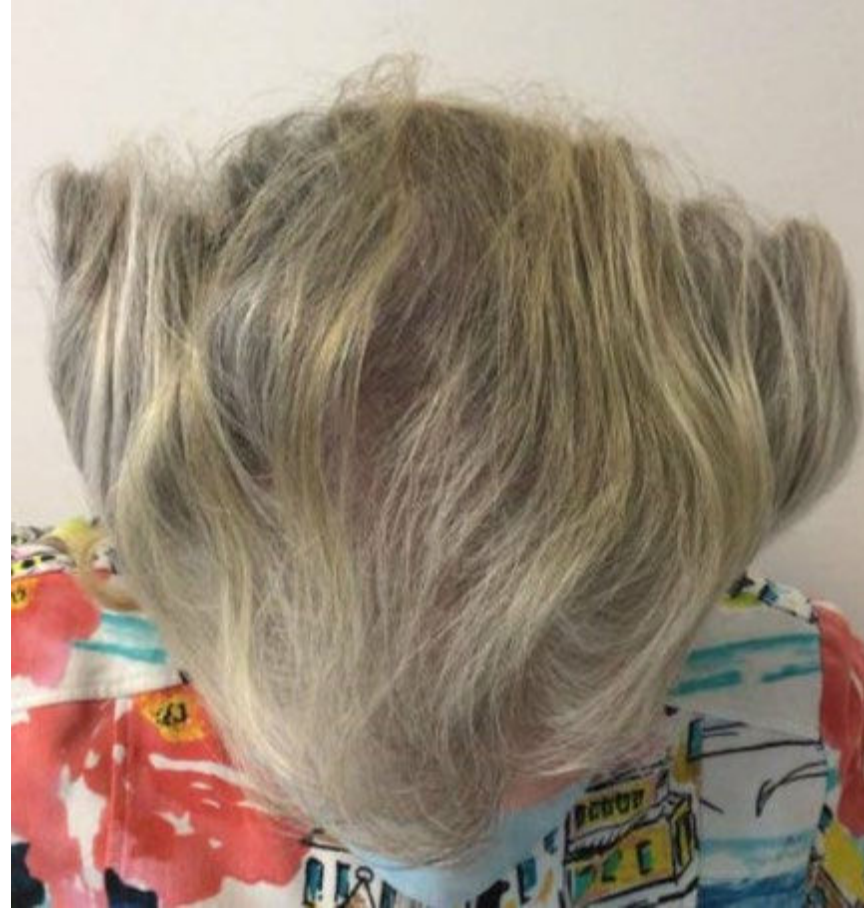

- **Actinic damage**
- **Start diclofenac sodium topical 3%**
 - **Not approved**

**75yo F,
s/p diclofenac 1% (OTC) TID x 6 months**



5 mo follow-up



1 year

Take GOOD photos!

Natasha A. Mesinkovska MD PhD